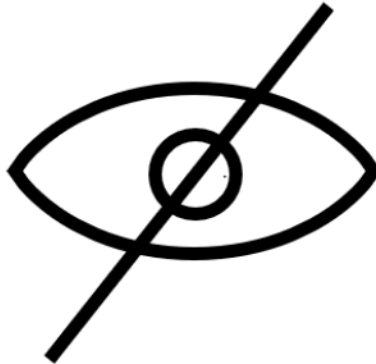




File: 292-30/LWR-2022-23324

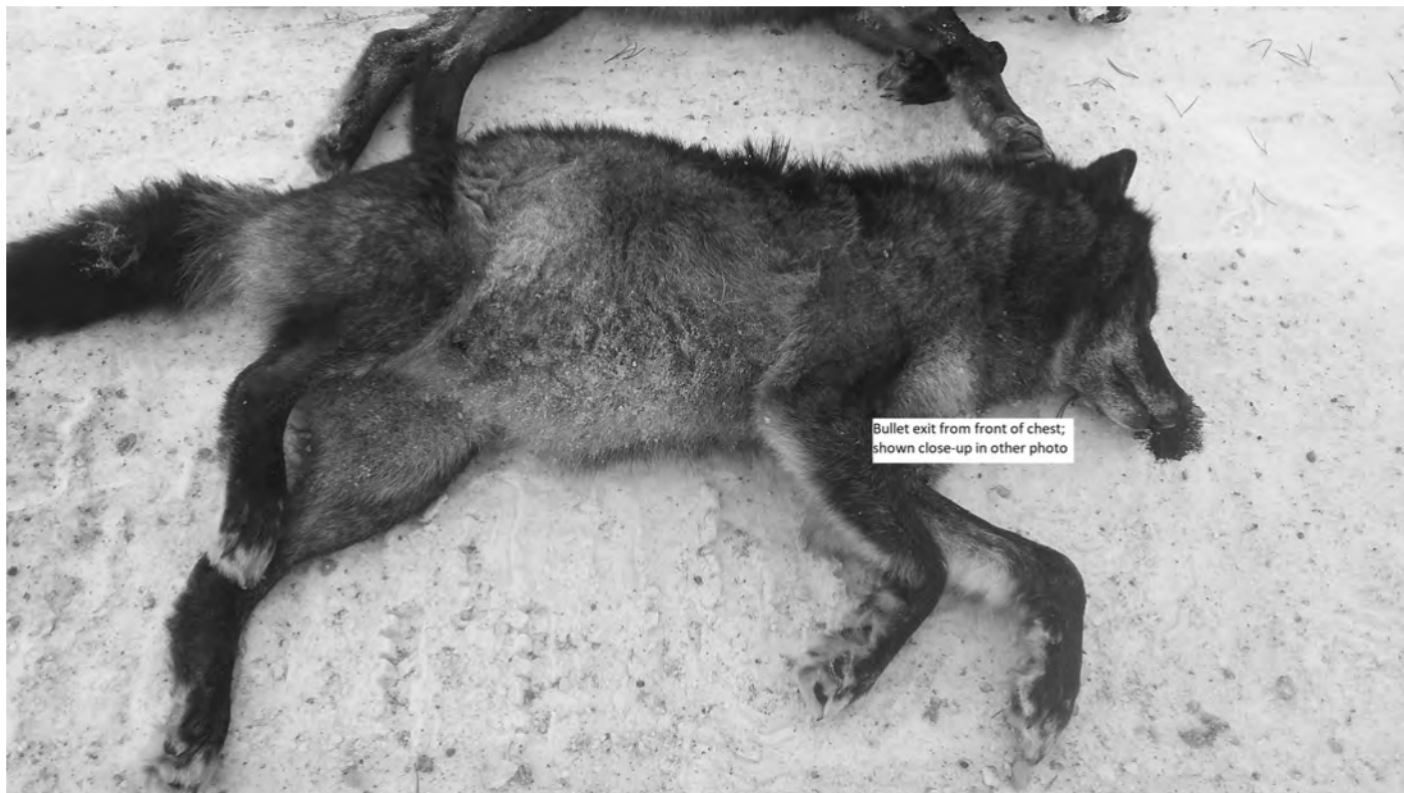WARNING

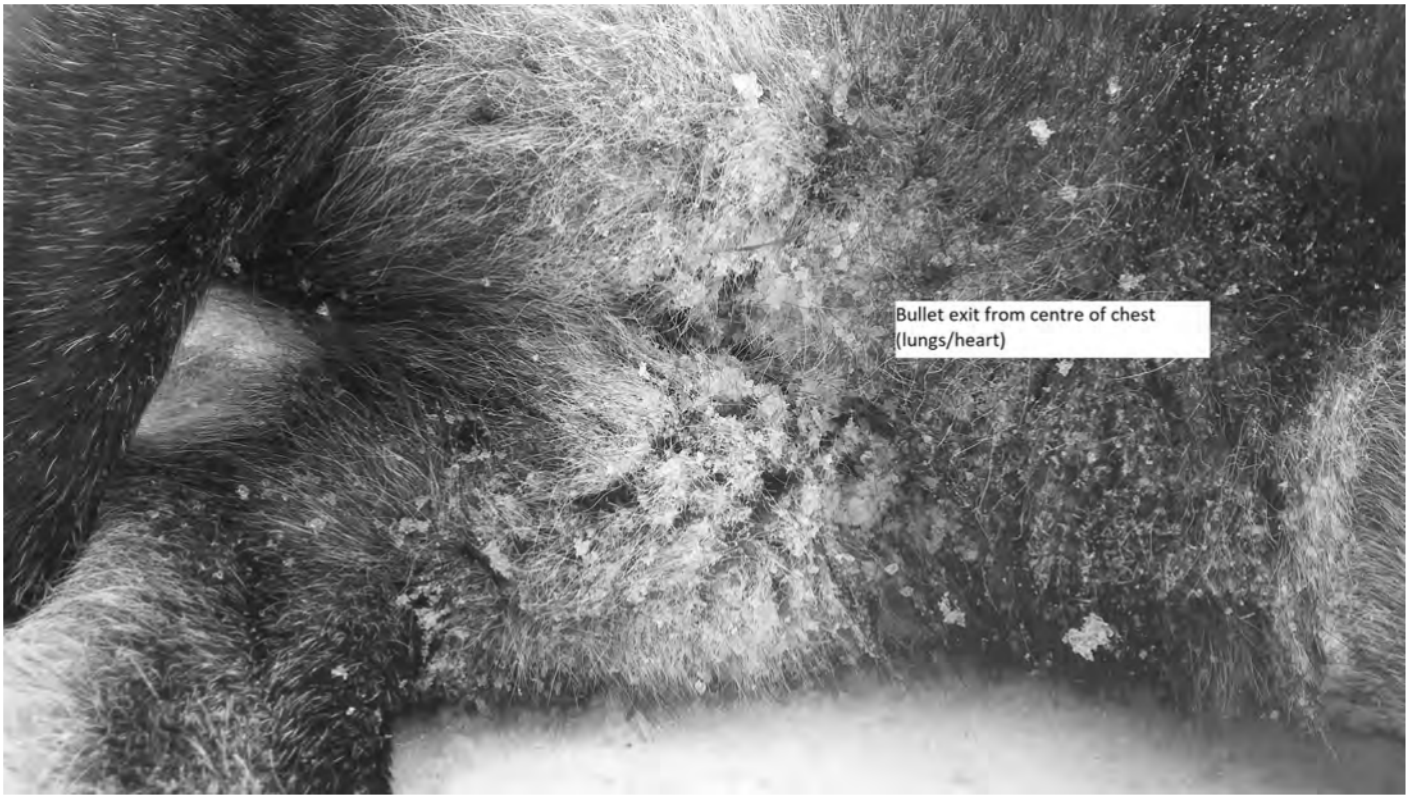
Sensitive Content






Wolf as it lays following instant
dispatch






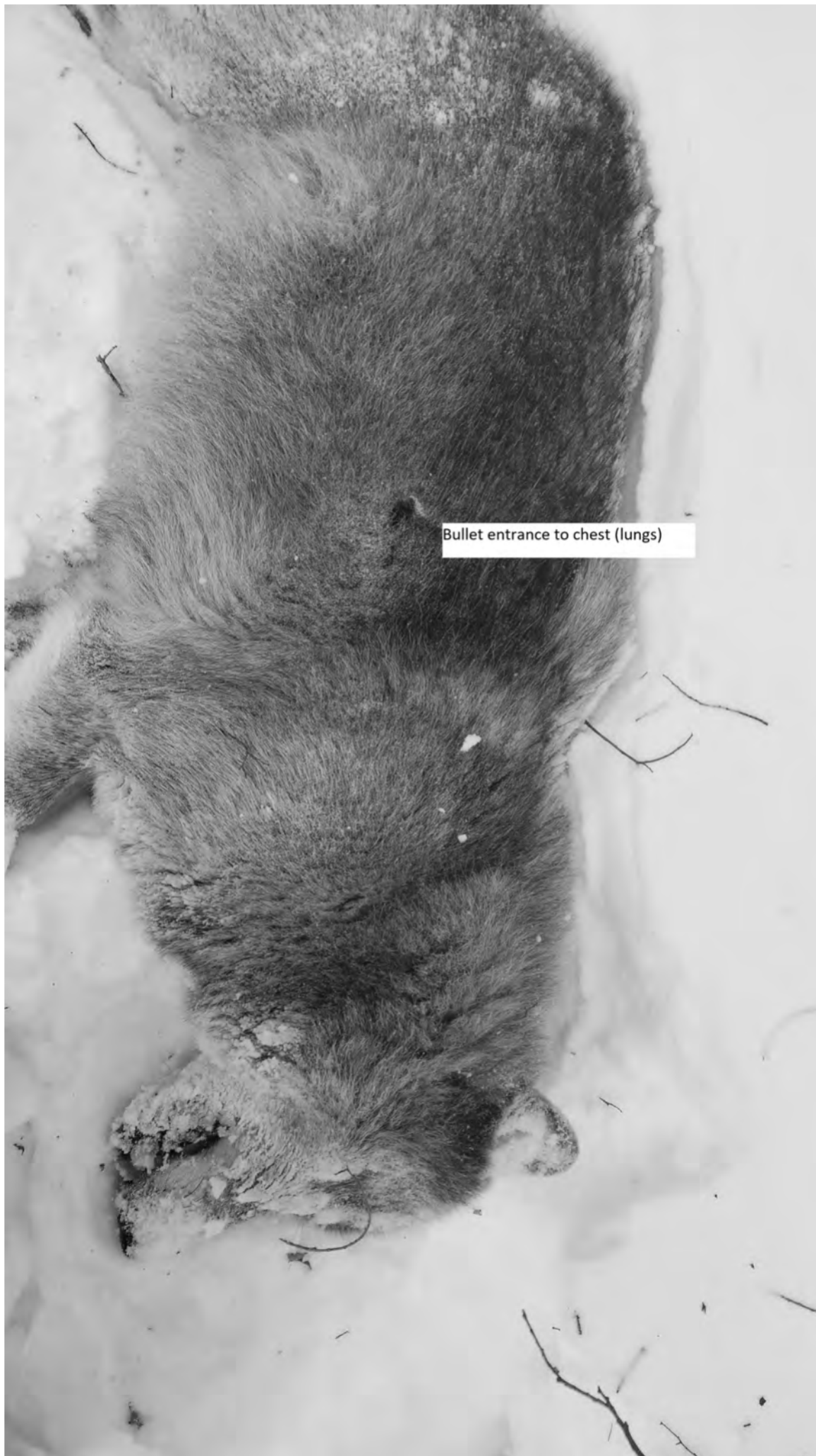

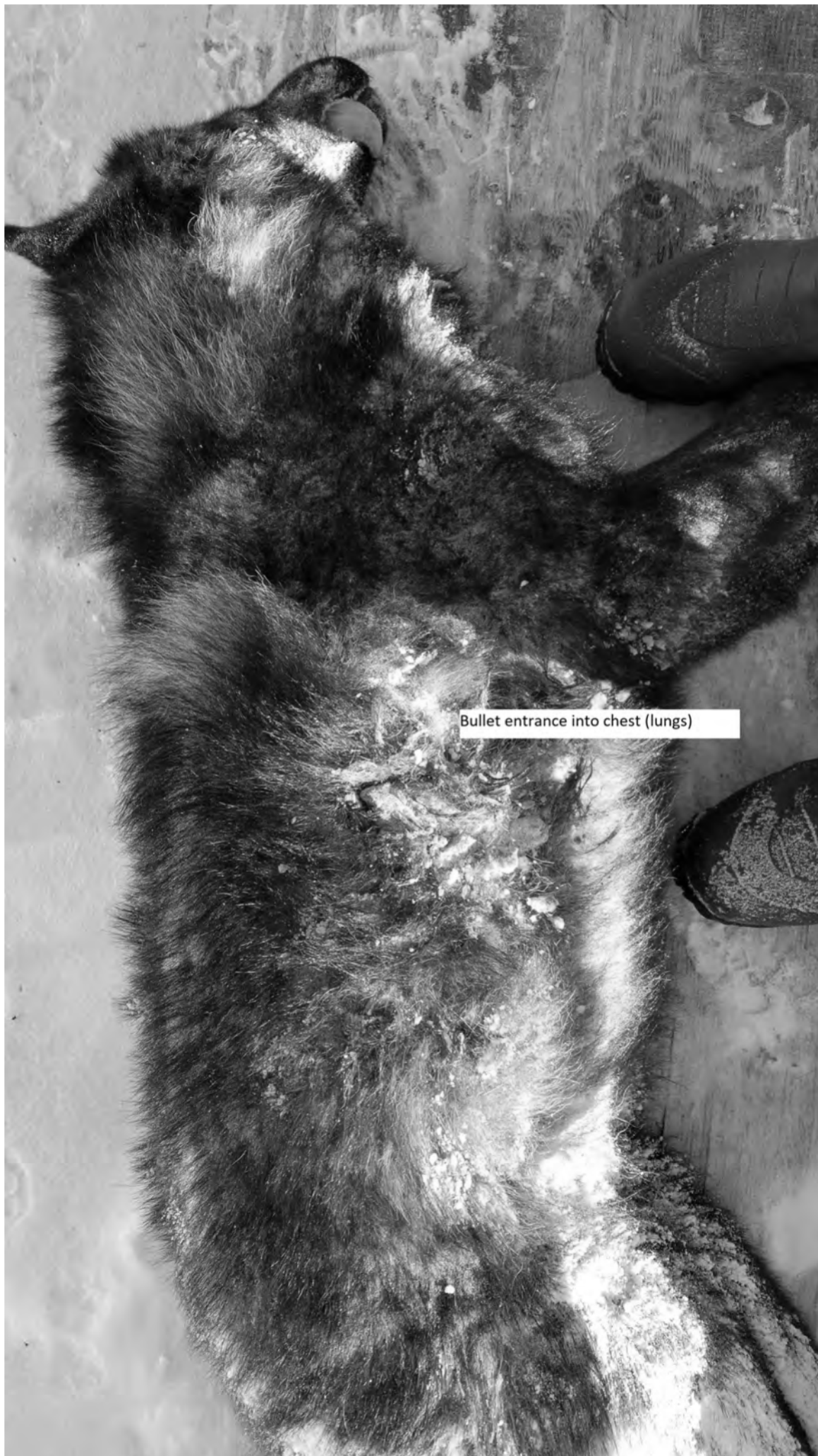
A black and white photograph showing a close-up of a dark-furred animal's body. A white rectangular text box is overlaid on the image, containing the text "Bullet entrance downward into chest cavity (lungs/heart)". The animal's fur is dark and appears slightly matted or stained around the area indicated by the text. The background is a light, sandy surface.

Bullet entrance downward into chest
cavity (lungs/heart)











Bullet entrance into chest (lungs)




Bullet exit through abdomen; entry into right
front shoulder/chest (lungs)

A black and white photograph of a dead animal, possibly a coyote or wolf, lying on a light-colored, textured surface. The animal's head is at the top left, and its body extends towards the bottom right. Two distinct bullet entry wounds are visible on the animal's neck/spine area. A white rectangular box with black text is overlaid on the image, pointing to these wounds. The animal's fur is dark and appears matted. The background is a light, grainy surface.

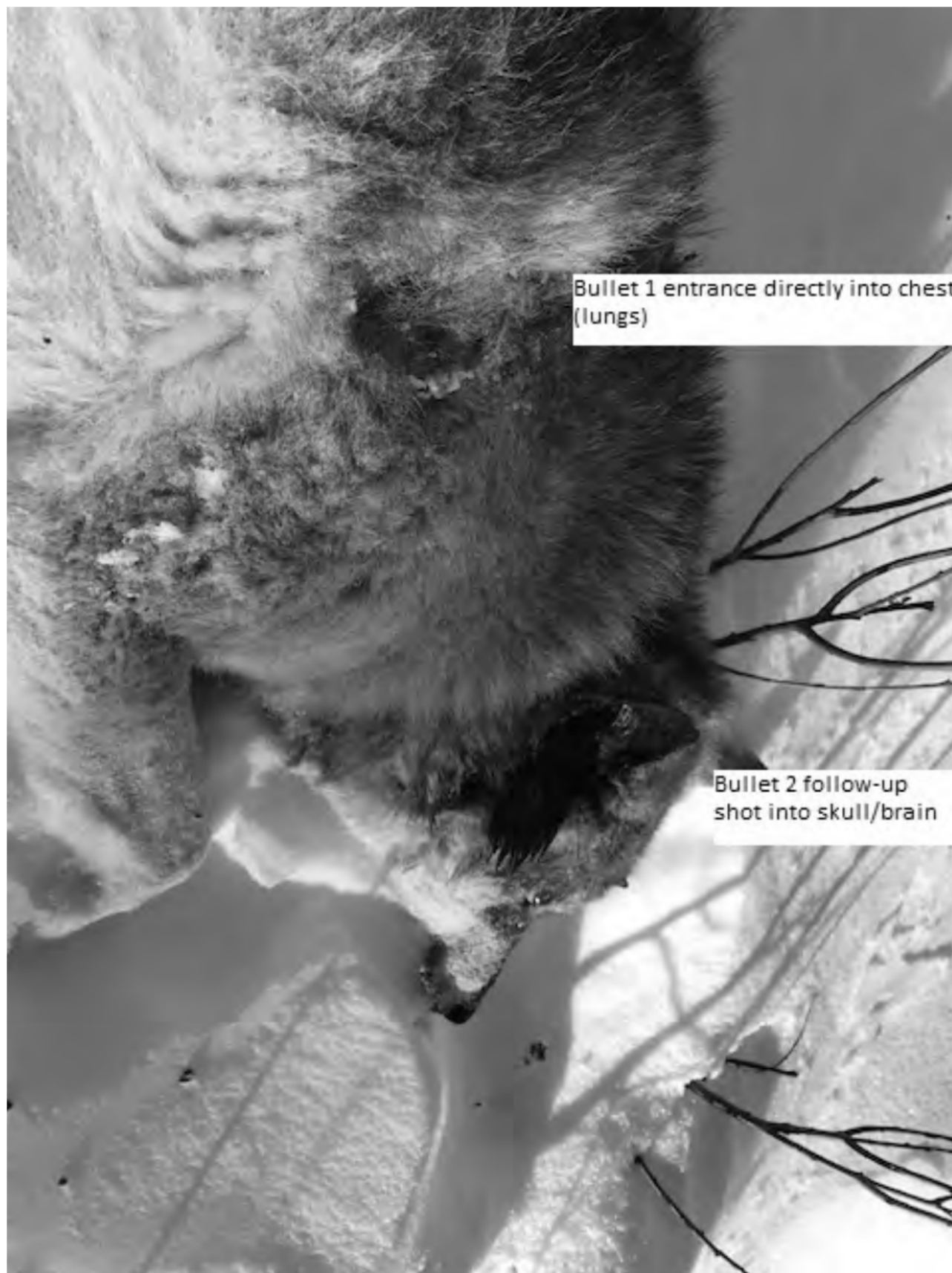
Two bullet entries into
neck/spine






A black and white photograph showing the neck and head of a dead animal, possibly a coyote or wolf, lying on a light-colored, textured surface. The animal's head is tilted back, and its mouth is slightly open. A dark, irregular mark on the side of the neck indicates a bullet entrance. A white rectangular box with black text is overlaid on the image, pointing to this mark.

Bullet entrance into
neck/spine



Bullet 1 entrance directly into chest (lungs)

Bullet 2 follow-up shot into skull/brain



Bullet exit; One shot through skull/brain





Bullet entry through chest (lung/heart)

Secondary bullet entrance through neck/spine





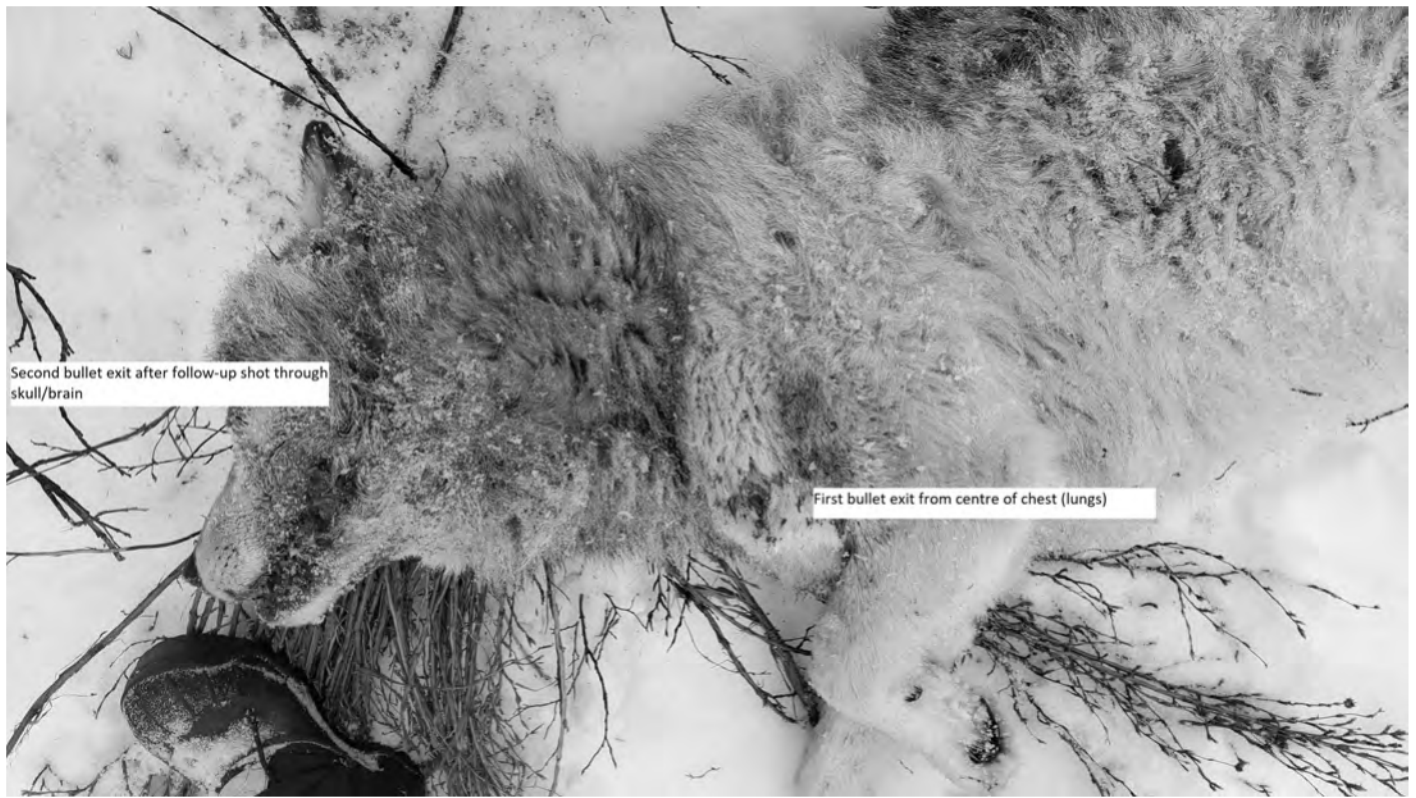
Additional photo displaying bullet exit(s)
through chest



Photo depicting final disposition of
wolf following instant dispatch



Bullet exit in centre of chest/sternum
after traveling vertically through spine
and chest (lungs) for an instant dispatch

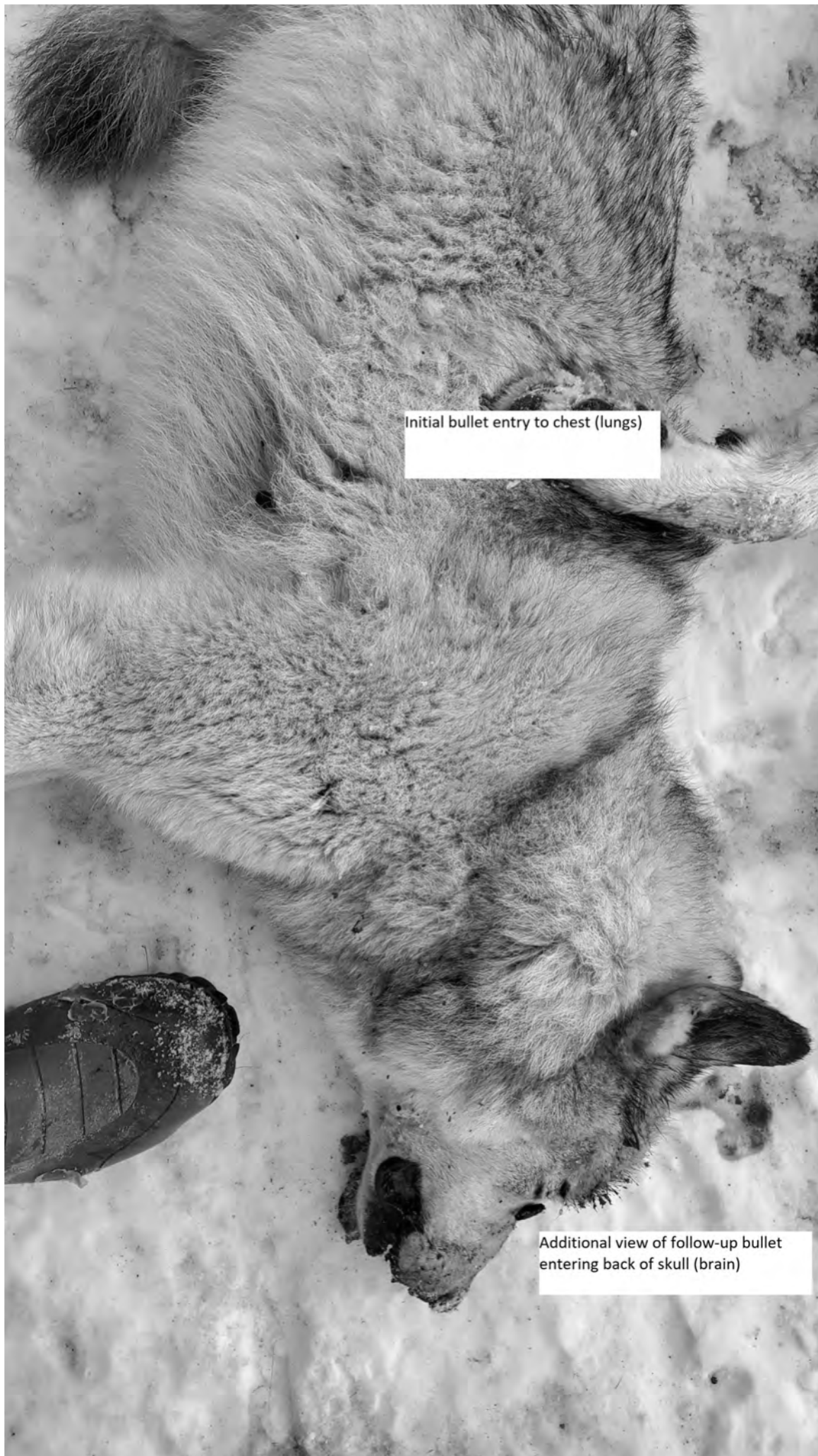




Bullet exit after single shot to skull/brain

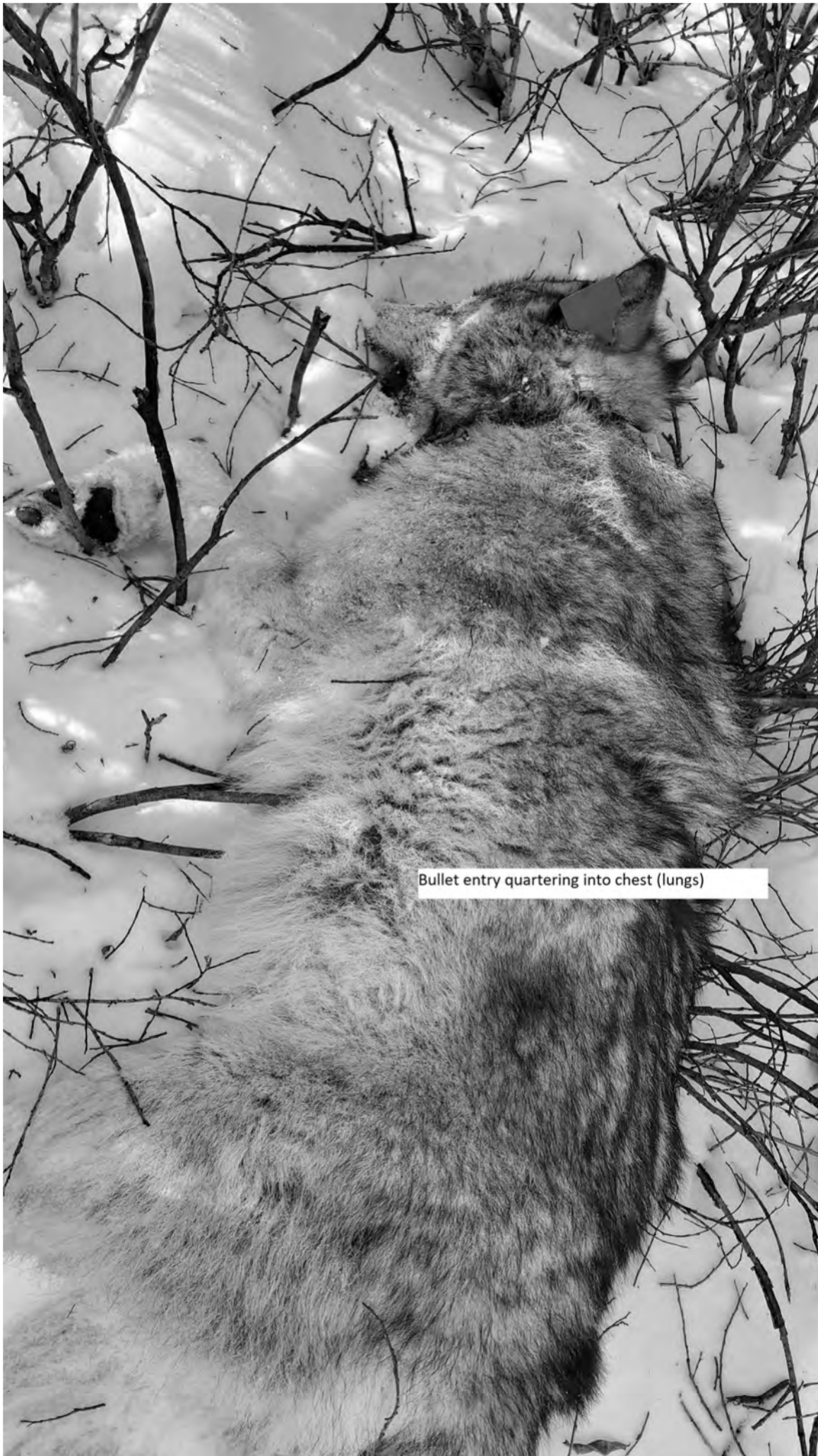Old wound/bite marks to hamstrings from other wolf, presumably







Initial bullet entry to chest (lungs)


Additional view of follow-up bullet
entering back of skull (brain)
















Close-up
Bullet entrance through front
of skull (brain)

A black and white photograph showing the back and neck of a dead animal, possibly a bear, lying on a snowy surface. The animal's fur is thick and dark. Two bullet wounds are visible: one on the lower chest and another on the neck/spine. A small, dark object, likely a bullet casing, is visible near the neck wound. Two white text boxes with black borders are overlaid on the image to identify the wounds.

Secondary bullet into
neck/spine

Initial bullet entrance through
lower chest (heart)










Photo depicting instant dispatch
of wolf




Photo depicting instant
dispatch of wolf



Bullet exit after passing through chest (lung/heart) and angling out lower shoulder











